

Human identification through the analysis of dental records registered in the context of a Dental Institution

Identificação humana pela análise do prontuário elaborado em uma Instituição de Ensino Odontológico

Mário Jorge TSUCHIYA¹
 Eduardo Menezes GOMES¹
 Daniela Miekó ABE¹
 Flavio Veras Nunes OLIVEIRA¹
 Carla MASSAOKA¹
 Rogério Nogueira OLIVEIRA²

ABSTRACT

Forensic Dentistry is a dental science with a broad field of activities, one of the most important is human identification. One of the main methodological resources to identify carbonized human remains is the comparative analysis of the dental records - antemortem data - with the postmortem data found in the remains. Specifically in this case it was possible to unveil the person's identity with the aid of a detailed radiographic image obtained in the emergency sector of a dental institution. It must be stressed however, that the dental records of this patient (with the dental treatment planning and anamnesis) were carelessly registered or even incomplete. It is important to note that the emergency services have the duty of not neglecting the process of obtaining information to fill the dental files of their patients, as this would turn the human identification process almost impossible, with dire personal, social, juridical and humanitarian consequences.

Indexing terms: Cadaver. Clinical record. Forensic anthropology. Forensic dentistry. Radiography, dental.

RESUMO

A odontologia legal é uma especialidade odontológica que possui uma ampla gama de atuação com destaque para a identificação humana. No contexto da identificação humana um dos principais recursos metodológicos para chegar-se a identidade de corpos carbonizados é a análise comparativa do prontuário odontológico - dados antemortem - com as informações encontradas no exame necroscópico - dados postmortem. No caso em tela a afirmação da identidade do indivíduo foi possível principalmente pela presença de documento radiográfico constante do prontuário clínico elaborado no setor de urgência de uma Instituição de Ensino Odontológico, radiografia esta com riqueza de detalhes e particularidades. Entretanto, ressalta-se que as fichas clínicas (anamnese e planejamento) constantes do referido prontuário mostraram-se sucintas ou mesmo incompletas. Não sendo escusa a serviços de urgência negligenciar o protocolo de elaboração do prontuário clínico odontológico, uma vez que tal prerrogativa poderia inviabilizar o processo de identificação humana, com conseqüências pessoais, sociais, jurídicas e humanitárias.

Termos de Indexação: Cadáver. Ficha clínica. Antropologia forense. Odontologia legal. Radiografia dentária.

INTRODUCTION

The knowledge and teachings of forensic dentistry go back a long way, both in Brazil¹⁻² and abroad³⁻⁵. Accuracy in filling out the clinical record charts is a basic requirement to make it possible to provide clarification in the process of human identification⁶⁻⁷. However, the documentation brought for comparison may present failures relative to concise and precise brevity, thereby losing the description of relevant data, or by the complete absence of records that make it unfeasible to attempt any comparison.

Knowing that human identification based on dental parameters is an efficient option in cases in which other methods of identification are unfeasible⁸ and that for this purpose, requires a dental record chart that contains characteristics, information and details about the individual being investigated^{6,9}, the aim of the present study was, by means of a real clinical case, to reinforce the need for strict fulfillment of clinical protocols that will provide not only elements for adequate clinical diagnosis and planning, but also antemortem data for comparison in processes of human identification¹⁰.

¹ Instituto Médico Legal de São Paulo, Núcleo de Odontologia Legal e de Antropologia. São Paulo, SP, Brasil.

² Universidade de São Paulo, Faculdade de Odontologia, Departamento de Odontologia Social. Av. Prof. Lineu Prestes, 2227, 05508-000, São Paulo, SP, Brasil. Correspondência para / Correspondence to: RN OLIVEIRA. E-mail: <rogerion@usp.br>.

CASE REPORT

In October, 2008, the Medical-Legal Institute of São Paulo ("Instituto Médico-Legal de São Paulo - IML-SP) received a carbonized cadaver for the purposes of identification. In view of the impossibility of collecting digital impressions and direct recognition (Figures 1 and 2), the remains were submitted to forensic medical and dental identification.

A person appeared at the IML-SP, informing that his/her father had been missing since 8/10/2008. According to the report, his wallet had been found two days after he/she had seen him for the last time. The person declared that the suspicion that the body may be at the IML-SP resulted from the discovery of two persons carbonized in the same region of the city, and that friends of his/her father's had seen tennis shoes similar to those his/her father had used at the scene of the crime.

The informer related that the individual being sought was black, height approximately 1.70m, weight 58 kilos, curly hair with white threads, small clothing size and shoe size number 40. He also had some dental characteristics: There were diastemata between the anterior teeth, absence of maxillary and mandibular posterior teeth, and he had received care at the emergency service of a dental teaching institution.

The Teaching institute was requested to provide the patient's dental clinical record chart for forensic dental comparison with the dental arches of the carbonized cadaver being investigated. The Institution provided the records of the case - charts (Figure 3) and radiograph (Figure 4) - informing that the patient in question was attended to in the emergency sector and received treatment in teeth 16 and 27.

Dental records elaborated by the teaching institute

Although the priority in cases of urgency is to minimize the suffering and possible systemic complications of the patient, this principle must not compromise the elaboration of an adequate clinical record¹¹.

In the case under review, in spite of the information contained in the record chart having been sufficient to confirm identification of the carbonized body, it was verified that the anamnesis chart omitted some of the patient's personal data. On the initial clinical exam, the notes were restricted to the description of the clinical procedures performed to attend to the urgent needs of teeth 16 and 27, with the outstanding features being biopulpectomy, temporary sealing of tooth 27 and necropulpectomy, with

prior radiograph taken of element 16. The notes on the record chart restricted to these two teeth reduced the data for confrontation, making the periapical radiograph the most significant document with a view to the investigation of human identification.

The radiographic image (Figure 4) emphasized the following peculiarities: The radiolucent area on the distal surface of the crown of tooth 15, compatible with caries; solution of continuity with loss of substance in the mesial cervical portion; positioning, coronal morphology, conformation of the pulp chamber and singular shape of the root canal (bifurcation of the canal as from the middle third of the root); radiolucent area, compatible with caries, on the mesial and occlusal surfaces of tooth 16, extending from the pulp chamber and cervical third of the root canals; solution of continuity with loss of substance in the cervical third of the distal root; positioning, anatomic conformation of the crown, roots and root canals; positioning, coronal morphology, conformation of the pulp chamber and root canals of element 17; positioning, anatomic conformation of the crown, roots and root canals; positioning, coronal morphology, conformation of the pulp chamber and root canals of element 18, presence of image compatible with calculus on the cervical portion of the mesial face of the crown; horizontal bone loss pattern, affecting elements 18, 17, 16 and 15; vertical bone loss pattern on the mesial interproximal surface of tooth 15 and adjacent, and anatomy of the maxillary sinus cortical (extension to alveolar area) and its relationship with the roots of the dental elements observed.



Figure 1. Carbonized Body IML-SP (October, 2008).

Description of the material investigated

A carbonized body was received for exam, with the presence of remains of male genitalia, right foot wearing a tennis shoe without number. On external exam, when removing the shoe, part of the right leg and foot presented preserved skin of dark mulatto color. On examination of the cranium, a parietal-occipital extradural hematoma to the right was found, indicating vital reaction and action of a blunt instrument, which may have caused death by cranioencephalic traumatism. In the radiographic evaluation, no presence of radiopaque materials, such as the projectile of a firearm, or bone alterations of forensic medical interest were found.

Radiographs were also taken of the dental arches, with the purpose of reproducing the conditions of the periapical radiograph provided for comparison, with the object of finding possible coincidences between the dental arches examined and the radiographic images of the patient who had been attended at the Teaching Dental Institute.

Characteristics of the dental arches

The presence of a restoration with temporary cement is pointed out on the occlusal, mesial and lingual faces of tooth 16 and restoration with material having the same characteristics, on the occlusal surface of tooth 27, which also presented caries. Absence of elements and wear (attrition) were also observed on the occlusal and incisal surfaces of all the teeth (Figure 5).

Forensic-dental comparison

Radiographic exam of the molar region on the maxillary right side of the cadaver investigated (Figure 6) allowed finding of the following individualizing coincidences with the dental documentation sent: positioning, coronal morphology, conformation of the pulp chamber and root canals of elements: 18, 17, 16 and 15; singular shape of the bifurcation of the root canal of tooth¹⁵; bone loss pattern observed in elements: 18, 17, 16, 15 and adjacent; loss of dental substance in the cervical region of elements 15 and 16; location and shape of the image suggestive of calculus on the mesial surface of tooth 18: Anatomy of the maxillary sinus cortical (extension to alveolar region) and its relationship with the roots of the dental elements observed; coincidence with regard to dimensions, shape and location of restoration in temporary cement in tooth 16 of the cadaver, compatible with the patient's radiographic image, exhibiting an extensive radiolucent area (on the mesial, occlusal surfaces, pulp chamber and cervical third

of root canals) of tooth 16, submitted to necropulpectomy, according to the record chart sent (Figures 4 and 6) and coincidence with regard to the presence of restoration with temporary cement in tooth 27 of the cadaver, compatible with emergency endodontic treatment performed in the patient.



Figure 2. Detail of face of carbonized body IML-SP. (October, 2008).

| Data | Cód. Proc. | PROCEDIMENTOS CLÍNICOS - DESCRIÇÃO | Q t d | Dentes / Áreas | Fases / Raízes | Código do Aluno | Vistos | |
|---------------|------------|------------------------------------|-------|----------------|----------------|-----------------|-----------|-----------|
| | | | | | | | Professor | Disciplin |
| 8.15.06.01.08 | 326 | antemortem | | | | | | |
| | 384 | pulpectomia | | 27 | | 736 | | |
| | 356 | antemortem | | | | | | |
| 8.16.05.08 | 356 | RX PERIAPICAL | 1 | 16 | | 533 | | |
| | 334 | EXAME PERIAPICAL | 1 | 16 | | 533 | | |

Figure 3. Clinical chart elaborated at the urgency service of the Dental Teaching Institute with description of the procedures performed on 16/01/2008 and 16/5/2008.

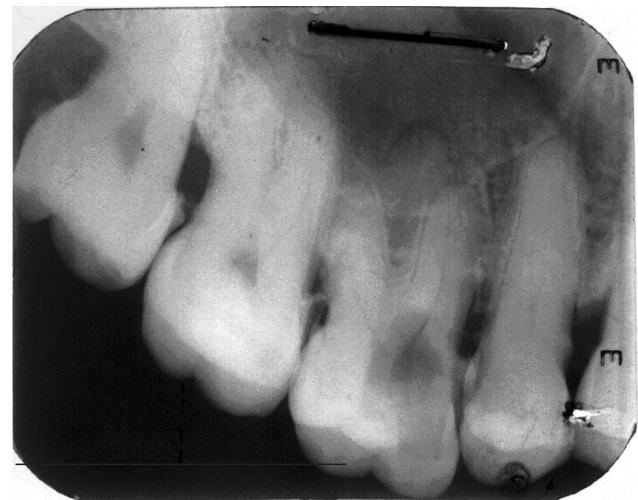

Figure 4. Radiograph taken at urgency service of Dental Teaching Institute (antemortem information).

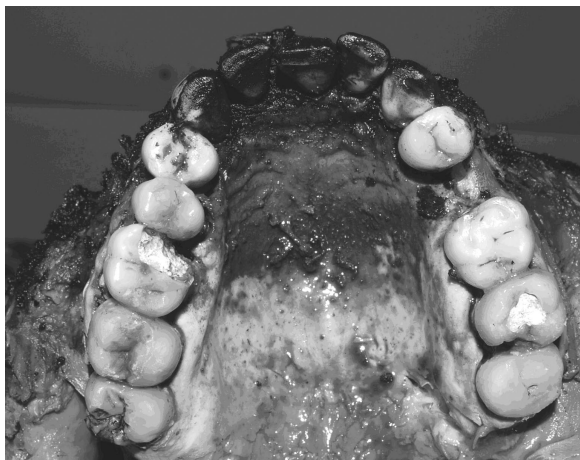


Figure 5. Maxilla with teeth 16 and 27 presenting temporary restorations (clinical condition compatible with that of the missing person).

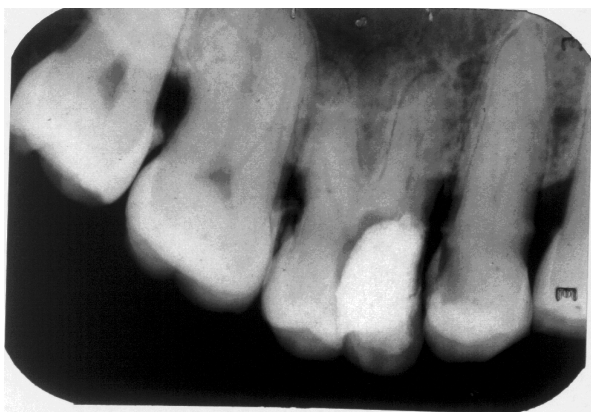

Figure 6. Radiograph taken at urgency service of Dental Teaching Institute (antemortem information).

DISCUSSION

The compatibility of the shoe found on the cadaver which the individual being sought was wearing, is not sufficient to affirm his identity. This correlation is made by lay persons, and is restricted to the field of recognition - in which identification is made without scientific methods, simply by the comparison of person objects, clothes or physiognomic similarities. These aspects are subject to innumerable alterations in the process of cadaver putrefaction, capable of mistakes and emotive confirmations, and not discarding criminal aspects of dissimulation. Thus, scientific methods of analyses, such as dental analyses - are essential in this process.

In the particular case of carbonization, in which it is impossible to apply the dactyloscopic method, comparison of the dental data is the method of choice, since the dental mineralization provides resistance to high

temperatures and other variations of the environment, due to the framework of the muscles and tongue keeping the teeth protected inside the oral cavity, preserving the dental elements against situations in which other superficial parts of the body are destroyed¹².

Since the victim's dental arches are in conditions to be analyzed, the success of forensic dental identification will be directly dependent on the previous meticulous dental documentation. Therefore the teaching, and consequently, the incorporation into professional practice of the use of protocols in the elaboration of record charts is imperative¹⁰.

More than merely exist, the previous dental record must bring clear and reliable information that allow comparison with that observed in the necropsied body. In the present case, the record chart elaborated at the Dental Teaching Institute was sufficient to enable the experts to reach a good closure. The radiographic image of the area of tooth 16 presented characteristics that were reproducible in the cadaver, resulting in a positive forensic-dental comparison.

The presence of the restorative material was shown to be compatible with the necropulpectomy performed, in agreement with the description on the attendance chart. In addition, the information on the clinical chart about the biopulpectomy procedure ratified that observed in the cadaver with regard to element 27, which presented a temporary restoration, although absent in the radiographic image.

However, it was noted that probably with the stage of the attendance being urgent, there was a summary description, with lack of details about the patient and about the other teeth not involved in the attendance. This descriptive economy is a relatively common fact in investigatory practice when dental documents sent for comparison are analyzed. This frequently restricts the collaboration of dentistry to radiographs or other imaging documents, which are not always sufficient to affirm an identity, or establish proof during discussion of a dental treatment in court.

But when images are present, they have broad potential in the investigatory context of estimating the age in the case of juvenile offenders¹³, or of persons without civil records, or as in the case here presented, to establish the individual's identity.

Irrespective of the causes, the fact of itself of providing nondescriptive details of the dental arches is a serious error, since the dental records do not always contain imaging documents. Consequently, if the dental

records provide an incomplete description, they may have no value whatever in the process of human identification.

In the present case, this failure did not compromise the process of identification, due to the presence of the radiographic document, but in the eventual absence of this, affirmation would be much more difficult, or may even be compromised.

With this case one finds that forensic dentistry demands the need for elaborating detailed clinical record charts, with a view not only to treatments, but also contemplating legal and humanitarian aspects when making feasible the human identification of a person.

CONCLUSION

The method of comparative dental analysis is efficient and decisive in the investigatory context of human identification.

In the elaboration of dental clinical record charts, protocols must be observed, since inconsistencies in their elaboration may compromise clinical follow-up as well as the possibility of identification.

REFERENCES

- Arbenz GO. Introdução à odontologia legal. São Paulo: Linografia; 1959.
- Lima FJA. Análise de características curriculares da disciplina odontologia legal nos cursos de graduação em odontologia do Brasil [dissertação]. São Paulo: Universidade de São Paulo; 2006.
- Acharya AB. Teaching forensic odontology: an opinion on its content and format. *Eur J Dent Educ.* 2006;10(3):137-41. doi: 10.1111/j.1600-0579.2006.00405.x.
- Herschaft EE, Rasmussen RH. The teaching of forensic dentistry: a status report. *J Dent Educ.* 1978;42(9):532-6.
- Stoeckel DC, Merkley PJ, McGivney J. Forensic dental training in the dental school curriculum. *J Forensic Sci.* 2007;52(3):684-6. doi: 10.1111/j.1556-4029.2007.00409.x.
- Meo IC. Análise da qualidade de prontuários odontológicos para fins de identificação humana através da auto-avaliação [dissertação]. São Paulo: Universidade de São Paulo; 2006.
- Sand LP, Rasmussen LG, Borrmann H. Accuracy of dental registrations in forensic odontology among dentists and dental students. *J Forensic Odontostomatol.* 1994;12(1):12-4.
- Rudnick SA. The identification of a murder victim using a comparison of the postmortem and antemortem records. *J Forensic Sci.* 1984;29(1):349-54.
- França BHS, Kuss DS. O prontuário clínico odontológico como meio de identificação. *JBC J Bras Clin Odontol Integr.* 2004;8(47):370-5.
- Brown KA. Procedures for the collection of dental records for person identification. *J Forensic Odontostomatol.* 2007;25(2):63-4.
- Assoumou NM, Gnagne-Agnéro Koffi ND, Avoaka Boni MC, Adou J, Adiko EF. Management of dental records: an example of the Department of Restorative Dentistry of the School of Odonto-Stomatology in Abidjan. *Odontostomatol Trop.* 2002;25(98):15-8.
- Remualdo VR, Oliveira RN. Potencial de análise forense do DNA de diferentes amostras biológicas. *Rev Assoc Paul Cir Dent.* 2005;59(6):421-4.
- Cornélio Neto WL, Conélio GC, Conceição MB. Estimativa da idade pelos 3º molares através de RX: relato de caso. *RGO - Rev Gaúcha Odontol.* 2006;54(3):230-3.

Collaborators

MJ TSUCHIYA, EM GOMES, DM ABE, FVN OLIVEIRA e C MASSAOKA participated in the dynamics of the service of identification which has a multidisciplinary characteristic (doctors, dental surgeons, radiologists, photographers, necropsy assistants, necropsy attendants, laboratory team for histological, anatomopathological, and DNA exams) in which all effectively participate in all the steps, right from receiving the material to be investigated, radiographic exams of the cadaver and its dental arches, photography procedures, the part of the media, with digitization of the images, and the result of the entire work of investigation results in the elaboration of a document that is called the expert report and writing of the article. RN OLIVEIRA participated in re-structuring this expert report into a scientific report suited to the scientific patterns with consistent bibliographic references, elaboration of the discussion focused on teaching and writing of the article.

Received on: 23/3/2009
Final version resubmitted on: 11/11/2009
Approved on: 9/8/2010